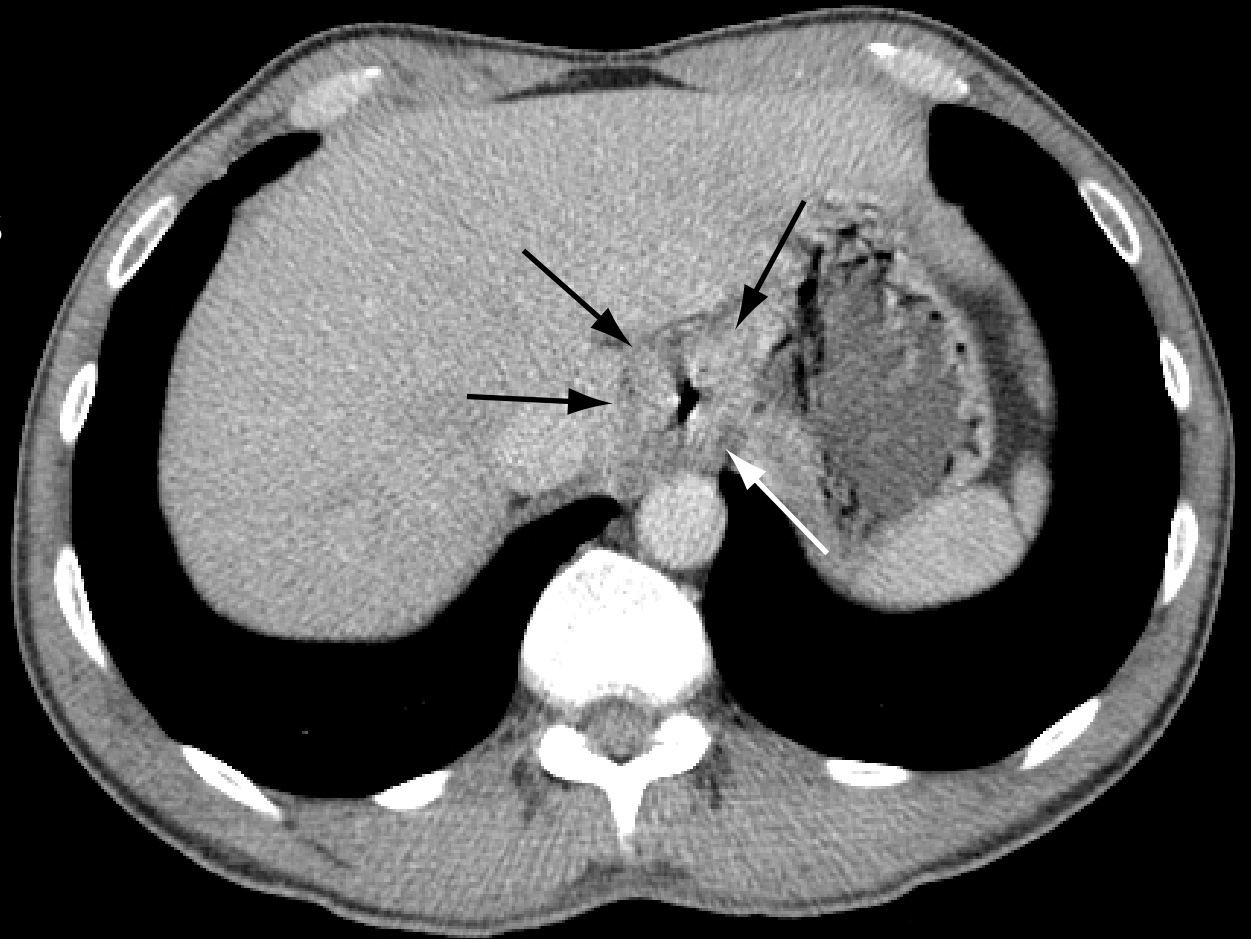
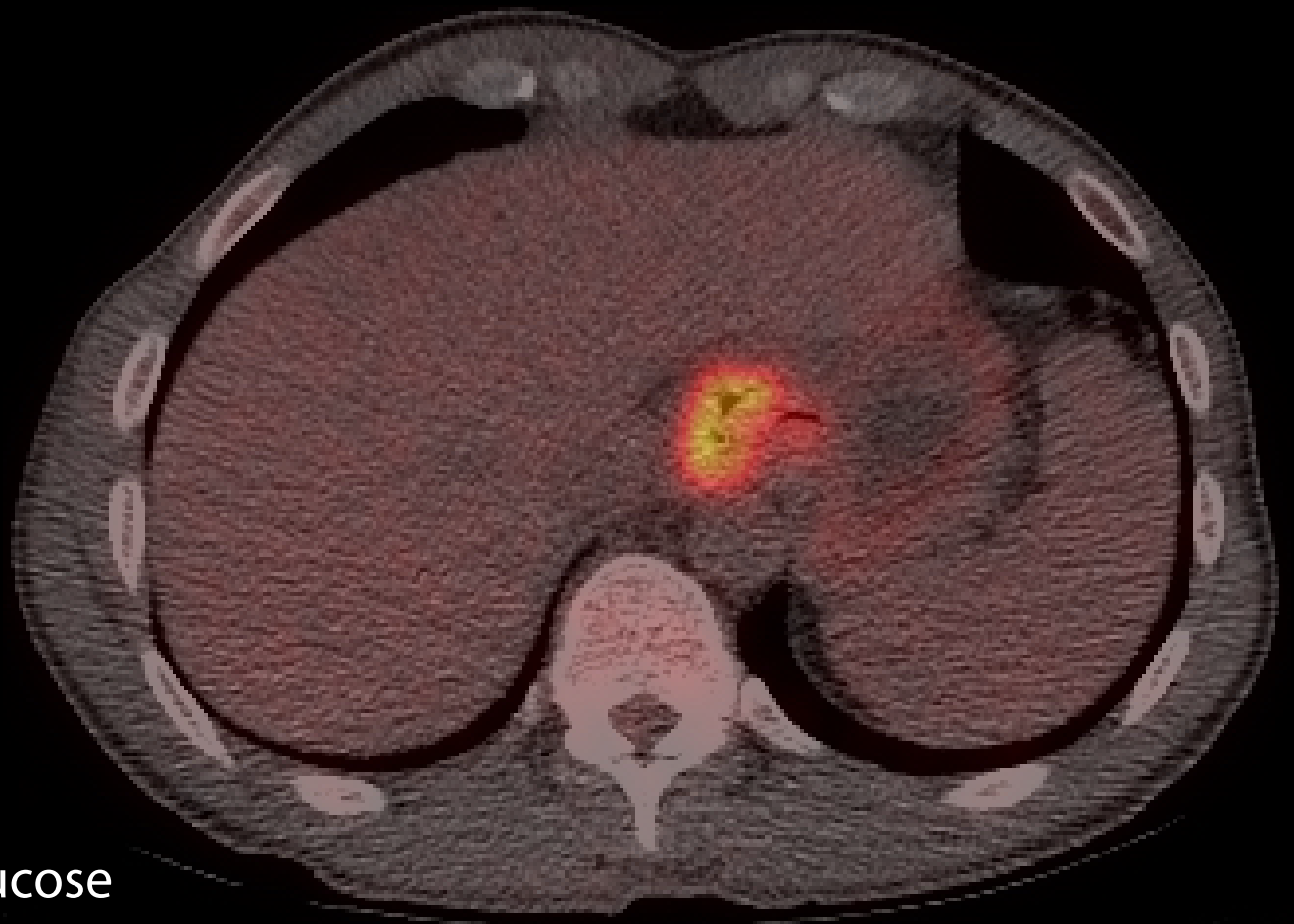


Carcinoma of the oesophagus demonstrated on CT and PET-CT.  
The PET scan was performed to look for evidence of secondary spread,  
which was not found.

Axial CT scan  
Oesophageal cancer  
outlined between arrows



PET CT scan  
High uptake of FGD\* on  
CT-PET at site of  
primary growth



\*FDG: <sup>18</sup>FluoroDeoxyGlucose