

Case 120 A missing testis



Figure 120.1

This 19-year-old college student, a keen footballer, was admitted to the orthopaedic unit for arthroscopic excision of a loose body from his left knee. When he was fully examined by the surgeon preoperatively, it was noted that the patient's right testis was absent, nor could a testis be felt along the line of the right inguinal canal, or at the base of the penis (Fig. 120.1). The left testis was normal in size and position. There was no history of previous surgery, nor was there any surgical scar. Surprisingly, the young man was completely unaware of the fact that he only possessed one testis.

What is this condition called?

The patient has a (previously undiagnosed) right undescended testis. The term cryptorchidism is often used to refer to the absence of a testis from the scrotum.

Apart from previous surgical removal, there are two other causes of an absent testis (or testes). What are these? And how are they differentiated from an undescended testis?

- *A retractile testis* (or testes): This is a normal testis where an excessively active cremasteric reflex draws the testis up to the apex of the scrotum or even to the external inguinal ring. It is a common phenomenon in babies and young children, but may be seen in adolescents. On careful examination, the testis can be coaxed into the scrotum. Moreover, the patient (or the parents, in young children) may notice that the testis is in its normal scrotal position when the subject is relaxed in a warm bath.
- *An ectopic testis*: The testis has emerged from the external inguinal ring but has strayed into an 'ectopic' position – the commonest is in the superficial inguinal pouch, which lies in front of the external oblique aponeurosis. Other rare situations are the groin, the perineum, the root of the penis or the femoral triangle.

Figure 120.2 is an example of the commonest variety of ectopic testis. This 7-year-old boy has a normally placed left testis, of normal size for his age. The right scrotum is empty, but there is an obvious bulge in his right groin, which can be seen (arrowed) immediately above the examiner's index finger. This testis cannot be coaxed into the scrotum. It has thus emerged from the external inguinal ring and has then passed, ectopically, to its position in front of the external oblique aponeurosis. At operation, it was mobilized and easily deposited into the scrotum.

What are the complications of an undescended testis?

- Defective spermatogenesis: Sperm production depends on the testis being at room temperature. If the testis is malpositioned the testicular tubules commence to degenerate in early childhood. Bilateral undescended

Part 2: Cases

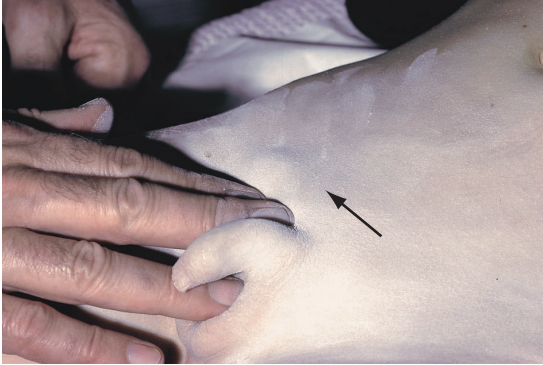


Figure 120.2 Ectopic testis.

testes, therefore, will result in sterility. In contrast, the interstitial cells of the testis, which secrete the male sex hormones, remain unaffected so secondary sexual characteristics develop normally at puberty in children with bilateral, untreated, undescended testes.

- Increased risk of testicular torsion.
- Increased risk of trauma: The tethered testis cannot slip away from a direct injury.
- Increased risk of malignant change, which remains true even if surgical correction is carried out. Figure 120.3 was taken at operation and shows a seminoma of an ectopic testis exposed in the groin of a man aged 32.

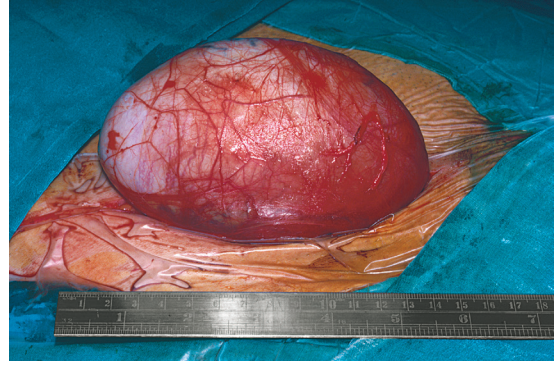


Figure 120.3 Seminoma of an ectopic testis exposed through an inguinal incision. Orchidectomy was performed.

- Psychological: Even young boys can be embarrassed by their anomaly.

What is the treatment of this condition?

The ectopic or undescended testis must be placed in the scrotum and this must be done before damage is done to the spermatogenic tubules. The operation is carried out around the age of 2. This procedure, termed orchidopexy, comprises mobilization of the testis and its cord, removal of the coexisting congenital inguinal hernia sac and fixation of the testis in the scrotum without tension.