

Case 99 An ulcerating breast lesion

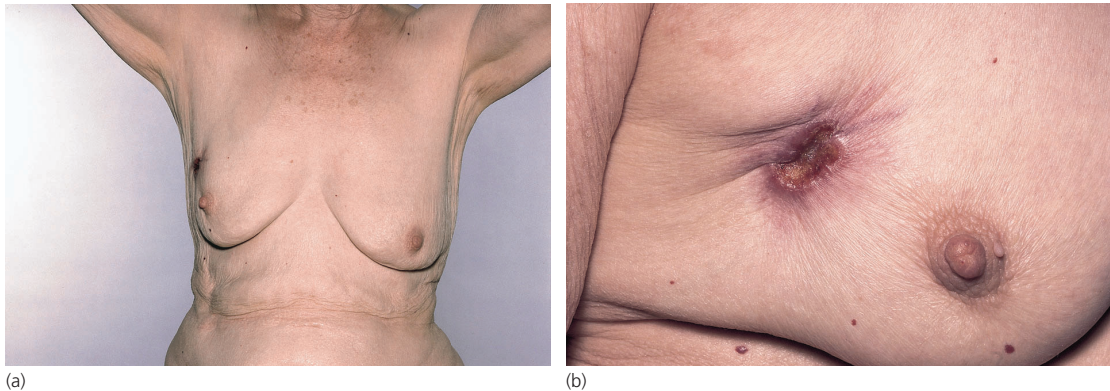


Figure 99.1

Figure 99.1 shows a general and close-up view of an ulcerating lesion of the right breast in a widow aged 75 years, who was referred urgently by her family doctor to the breast clinic of the local hospital. She explained that she had found a lump in the right breast 'about the size of a grape' about 2 years before. This gave her a terrible fright so she ignored it completely and did not consciously examine her breasts again. However, a few months ago this ulcer appeared and began to discharge and to bleed. She finally got enough courage to show it to her doctor. It was quite painless and she was otherwise well.

The patient had never had children and there was no one in the family, as far as she knew, who had had breast cancer. Her periods ceased when she was 45 years old. She lived on her own in a two-roomed flat.

What is the diagnosis?

She has, without much doubt, an ulcerating carcinoma of the right breast. In the Western world it is unusual to see patients presenting at such a late stage of the disease – although they still sometimes do. However, older clinicians will have seen many such cases decades ago and

such examples are still common in the developing world.

Enumerate the signs of advanced breast cancer that you can see in Fig. 99.1

There is an ulcerating lesion in the upper outer quadrant of the right breast. It has raised everted edges and there is puckering of the adjacent skin. The nipple is indrawn and the breast is somewhat shrunken and also elevated.

How common is carcinoma of the breast in the UK?

It is the commonest killing cancer of women in the UK and indeed in the Western world. In the UK there are 50 000 new cases annually, and it accounts for some 12 000 deaths.

Is it ever found in male subjects?

There is breast ductal tissue beneath the male nipple, which extends just outside the areolar margin – hence there are cases of gynaecomastia in the male at puberty or in response to stilboestrol. Carcinoma of the male breast accounts for roughly 1% of all cases. Because the

Part 2: Cases

male patient often thinks little of a painless lump in the region of the nipple, many cases in the male present at a fairly advanced stage.

Where would you examine this woman for evidence of dissemination of her tumour?

- *Lymphatic spread*: Examine the axillary and supraclavicular nodes on the affected side.
- *Blood spread*: Examine the liver, lungs, skeleton and CNS.
- *Transcoelomic spread*: Examine for the presence of ascites and pleural effusion.

Is anything known about the aetiology or predisposing factors of this common cancer?

In spite of much study, surprisingly little is known.

- There is a family tendency – a premenopausal first-degree relative, mother or sister, with breast cancer confers a lifetime risk of 25%, which reduces to 14% if the relative is postmenopausal at the time of her diagnosis. If both the mother and sister have developed breast cancer pre-

menopausally, the risk rises to 33%.

- The disease is rare in the Far East.
- An early age of commencement of periods (11 years or under) and a late menopause (51 years or over) are associated with higher risk – and both these factors are becoming more common.
- Nulliparous women have a higher risk than parous, and early age at first pregnancy appears to play a protective role, as does breastfeeding.
- Hormone replacement therapy may slightly increase the risk, and this is proportionate to the length of time of treatment.
- Carriage of the *BRCA1* and *BRCA2* genes are significant risk factors.

The chest X-ray, bone scan, abdominal ultrasound (for hepatic involvement or evidence of free fluid) and full blood count were normal. A biopsy of the ulcer edge, performed under local anaesthetic, showed a moderately well differentiated, invasive ductal carcinoma, oestrogen receptor positive. The patient was treated as an outpatient with radiotherapy and tamoxifen and the ulcer slowly healed.