

Case 91

A patient with jaundice and interesting physical signs

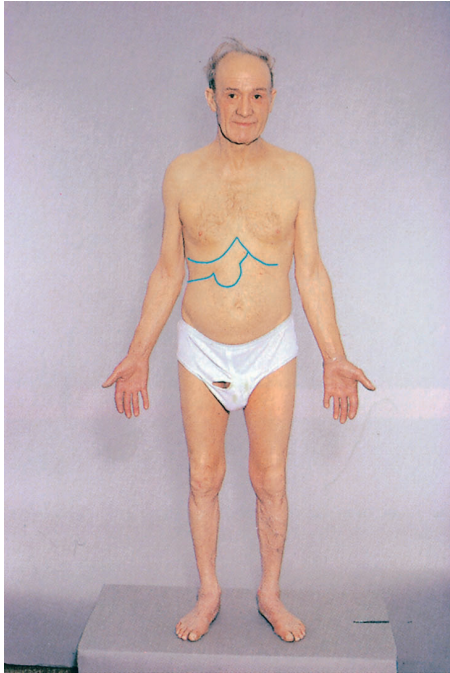

Figure 91.1

Figure 91.1 is a photograph of a lorry driver aged 60 years who was admitted to the surgical unit urgently from the outpatient clinic. About 6 weeks previously, his wife noticed that his eyes had turned yellow. His skin then became obviously discoloured and became itchy, his stools turned greyish white and his urine became dark brown. His appetite, normally excellent, became poor and he thought he had lost a few pounds in weight. However, he had experienced no abdominal pain or discomfort during this time. There was nothing relevant in the rest of his functional enquiry, past or family history. He was a non-smoker and a life-time teetotaller.

On examination he was a cheerful, well built man, but obviously deeply jaundiced. The abdominal signs were

striking, and have been outlined with a marker pen. There was a firm, smooth mass extending 5 cm below the right costal margin, which was dull to percussion, and this dull note extended up to the fifth rib in the mid-clavicular line. From its lower border, a globular mass projected towards the umbilicus. There was no clinical evidence of ascites and the supraclavicular nodes were not palpable. Rectal examination revealed a moderate smooth enlargement of the prostate and clay-coloured stool was seen on the examining finger. Apart from a Dupuytren's contracture of his left little finger and varicose veins of both legs, general examination was otherwise normal.

A ward test of his dark brown urine specimen was strongly positive for bile pigment.

What physical signs are demonstrated in this jaundiced patient's abdomen?

The liver is enlarged and the gallbladder is grossly distended.

What is the name of the law based on these signs and what conclusion can you draw from these?

Courvoisier's law,* which states that, in the presence of jaundice, if the gallbladder is palpable, the jaundice is unlikely to be due to a stone, or stones, impacted in the bile duct system and, therefore, is probably due to a tumour at the head of the pancreas which is obstructing the common bile duct.

Can you explain this phenomenon, which, in clinical practice, is found to be pretty reliable?

The law, and its exceptions, are explained in Fig. 91.2. Obstructive jaundice due to stones is usually associated

*Ludwig Courvoisier (1843–1918), Professor of surgery, Basle, Switzerland.

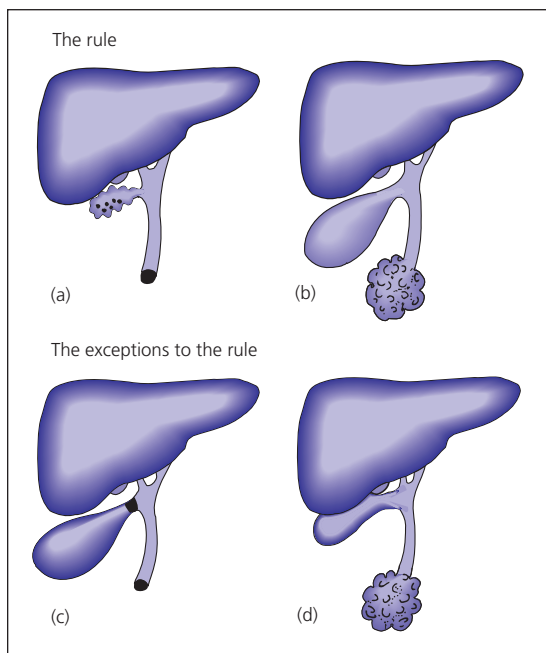


Figure 91.2 Obstructive jaundice due to stone is usually associated with a thickened contracted gallbladder (a). Therefore, in the presence of jaundice, a palpable gallbladder indicates that the obstruction is probably due to some other cause – the commonest being carcinoma of the pancreas (b). Exceptions to the rule are a palpable gallbladder produced by one stone impacted in Hartmann’s pouch resulting in a mucocele, another in the common duct causing the obstruction (c), which is a rare occurrence. Much more often, the gallbladder is indeed distended but is clinically impalpable (d).

with a thickened, contracted gallbladder (Fig. 91.2a; see Case 89, p. 183), which is incapable of becoming distended. Therefore, in the presence of jaundice, a palpable gallbladder is probably due to some other cause of

the obstruction, the commonest by far being a tumour at the head of the pancreas (Fig. 91.2b).

Exceptions to the rule are a stone impacted at the neck of the gallbladder producing a mucocele and another in the common duct causing obstructive jaundice (Fig. 91.2c), which is a rare occurrence. Much more often, the gallbladder is indeed distended but is clinically impalpable (Fig. 91.2d). This occurs in about half the cases of obstructive jaundice in pancreatic cancer.

In view of this patient’s complete absence of pain, what sort of pancreatic tumour may this patient have?

The absence of pain suggests that the patient has a periampullary tumour, arising in pancreatic tissue immediately adjacent to the termination of the common bile duct at the ampulla of Vater,† or in the duct itself, or, rarely, in the second part of the duodenum. This will result in early obstruction of the duct – with all the features of obstructive jaundice – before invasion of adjacent tissues produces pain. The majority of carcinomas of the pancreatic head present with upper lumbar and/or upper abdominal pain before jaundice becomes clinically obvious.

What physical sign, which you probably did not spot before, can you see on this patient’s underpants?

He has dribbled some urine onto his pants; this has evaporated, leaving a brown stain. Obviously he has bilirubinuria! It is a common sign to find in the ward on the jaundiced patient’s bed sheets, where there has been spillage from the urinal or bed pain. (This patient is further discussed in Case 92, p. 190.)

†Abraham Vater (1684–1751), Professor of anatomy, Wittenberg, Germany.