

Case 86 A postmortem finding

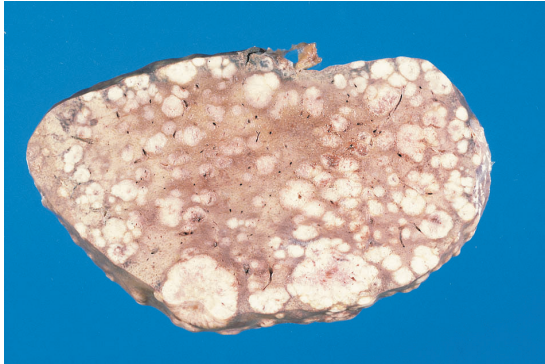


Figure 86.1

The patient described previously in Case 85 was submitted to postmortem examination 2 days after her death. The relevant findings were in the abdominal cavity. The omentum was adherent all along the previous abdominal incision, which was soundly healed. A large amount of ascitic fluid was present and was aspirated away. There was a large, fixed tumour mass that occupied the distal stomach, and was fixed to the posterior abdominal wall along the length of the pancreas. There were numerous enlarged, hard lymph nodes along both the gastric curvatures.

The striking finding was the liver, which was considerably enlarged and nodular. Figure 86.1 shows the appearance of a slice through it.

Describe what you can see in this specimen

The liver is almost replaced by widespread whitish deposits. Together with the clinical story, these are secondaries that have seeded to the liver from the primary gastric tumour via the portal vein.

What is the description of the characteristic cut surface of these lesions and what produces this appearance?

The cut surface has a depressed centre, described as an umbilicated surface. This is due to necrosis of the centre of the tumour, which has outgrown its blood supply from the adjacent blood vessels in the liver.

List the common primary sites for tumours that metastasize to the liver in the UK

Primary carcinomas of the lung, breast, large bowel and stomach account for the great majority of cases, although carcinomas at any site and malignant melanoma may metastasize to the liver. Malignant melanoma of the retina has a sinister reputation for this, hence the old surgical aphorism: 'Beware of the patient with a glass eye and a large liver'.

Approximately what proportion of patients dying of malignant disease will be found to have liver secondaries at autopsy?

About one-third of cases.