

## Case 77

# A patient with recurrent perianal sepsis

The patient, a 30-year-old schoolmaster, attended surgical outpatients with the following history – about 3 years previously he developed an abscess on his left buttock. This was drained as a day case at another hospital and healed up. However, since then, there have been repeated episodes of infection; a couple had been drained under anaesthetic at the same hospital and three more had burst spontaneously after sitting repeatedly – and painfully – in a very hot bath. Between these very acute episodes, he usually noticed a discharge of smelly, sticky material near the anal verge and he had to keep a pad of cotton wool within his underpants to prevent his clothes from being soiled. On several occasions he had the impression that flatus was escaping at the site of these infections.

**Just on this story you should be able to make a provisional diagnosis of what the condition is**

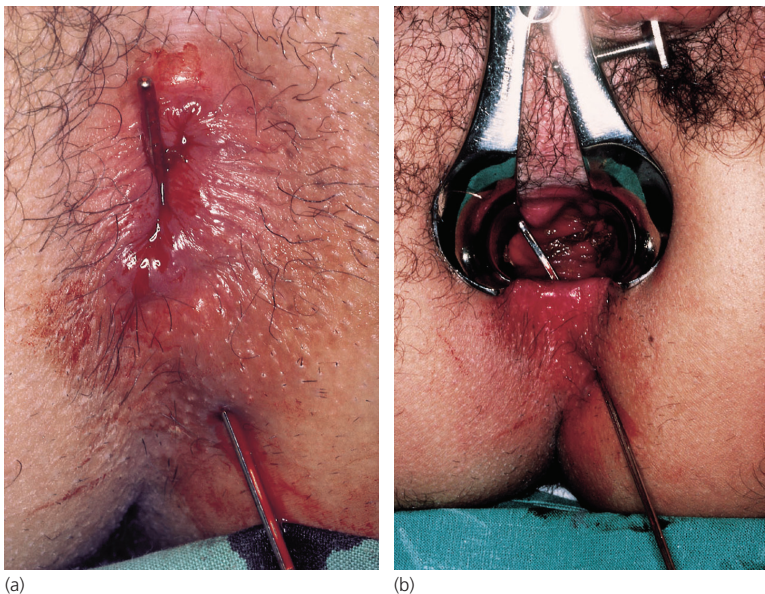
A fistula in ano.

### What is the definition of a fistula?

A fistula is a pathological communication between two epithelial surfaces. This may be between two hollow viscera, for example a tracheo-oesophageal fistula or a vesico-colic fistula, or between a hollow viscus and the skin, as in this case or an intestinal fistula onto the abdominal wall.

**The patient was admitted semi-urgently for operative treatment. Figure 77.1 shows the patient's perineum as he lies anaesthetized on the operating table in the lithotomy position. What is demonstrated?**

In Fig. 77.1a a fine probe has been passed from the external opening of the fistula at the 5 o'clock position and is seen to emerge from the anal canal. In Fig. 77.1b a self-retaining anal retractor has been inserted and the internal opening of the fistula can be seen in the midline (the 6



**Figure 77.1** Operative photographs of the patient's perineum.

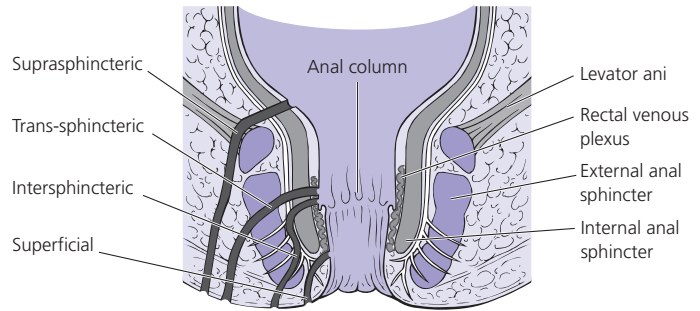


Figure 77.2 The anatomy of perianal fistulae.

o'clock position) fairly low down the wall of the anal canal.

### What is the common underlying cause of this condition and what are the rarer causes?

The great majority result from an initial ischio-anal abscess, which ruptures onto the perianal skin and into the anal canal. This was obviously the underlying cause in the present case (see Case 76, p. 152). Rarely, fistulae may be associated with Crohn's disease (where they are often multiple), ulcerative colitis, tuberculosis and advanced carcinoma of the rectum.

### How are fistulae in ano classified?

Anal fistulae are classified according to their position and relationship to the internal and external anal sphincters:

- *Superficial:*
  - Submucous.
  - Subcutaneous.
- *Low anal:*
  - Intersphincteric.
  - Trans-sphincteric.
- *High anal:*
  - Suprasphincteric.
- *Anorectal.*

These are demonstrated in Fig. 77.2. The superficial and low anal fistulae are by far the commonest.

### What is the treatment of fistulae in ano?

This is invariably surgical. Superficial and low level anal fistulae are laid open along their length and are allowed to heal by granulation. Because no sphincter, or only the subcutaneous parts of the internal and external sphincters, is divided in this procedure, there is no danger of loss of anal continence. Fistulae can only be treated in this manner when they quite definitely lie below the level of the anorectal ring. Careful assessment of the level of the internal opening of the fistula must therefore be made preoperatively and if there is any clinical doubt about the level, endo-anal ultrasound examination must be carried out using an anal probe. This gives a very accurate localization of the track in relation to the sphincters.

In the case of high fistulae (suprasphincteric or high intrasphincteric close to the anorectal ring) a non-absorbable strong ligature, usually nylon, is passed through the upper part of the tract and is left in place for 2 or 3 weeks so that the deep part of the sphincter becomes fixed by scar tissue – this ligature is called a seton.

It is serially tightened over a period of time and cuts through the sphincter which heals behind it progressively, preserving continence.