

## Case 62

# An unusual case of severe rectal bleeding in a child

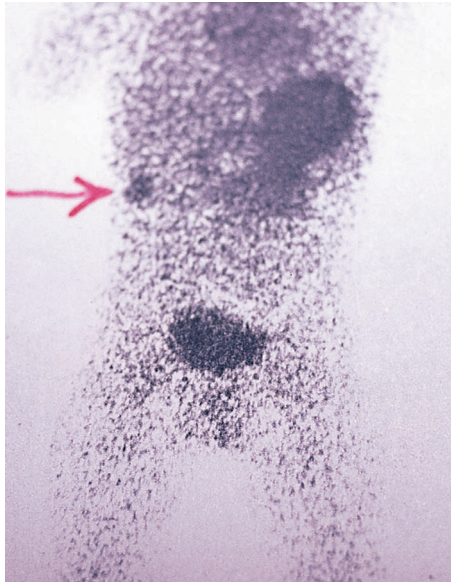


Figure 62.1

A 7-year-old boy was admitted to the paediatric surgical unit as an emergency. The mother gave the history. He was a previously perfectly healthy child, apart from the usual coughs and colds and one episode of otitis media, which had been treated with antibiotics. Early on the morning of admission, he woke up and rushed to the toilet with an urgent desire to defecate. He called his mother, who found him very pale and who saw that they contained a large amount of dark red blood and clots. This had never happened before. The family doctor was called, who arranged his urgent hospital admission.

On examination, the child was frightened and crying but not in any pain. The mucosae were pale. His pulse was 110 beats/min and blood pressure 100/70 mmHg. Abdominal palpation was entirely normal – there was no tenderness or masses. Rectal examination was normal, but the glove was streaked with dark blood.

His condition rapidly returned to normal after a blood transfusion.

In view of these negative findings, an urgent radionuclide scan was performed using technetium-99m. The scan is shown in Fig. 62.1 and, to help you with this, the abnormality that was disclosed is labelled with a pointer.

### What normal and abnormal structures are demonstrated on the child's scan?

The large shadow in the upper left side of the abdomen is the stomach, where the radionuclide is taken up by the acid-secreting parietal cells in the gastric mucosa. The shadow in the pelvis is the bladder, where the radioactive material has been excreted in the urine. The small shadow that has been arrowed is the typical appearance produced by the parietal cells in the ectopic gastric mucosa lining a Meckel's diverticulum.\*

### What, therefore, was the cause of the child's haemorrhage?

Hydrochloric acid, secreted by the ectopic gastric mucosa in the Meckel's diverticulum, has produced ulceration in the diverticulum or in the adjacent ileum. The haemorrhage has resulted from erosion of a vessel in the ulcer wall.

After restoring the child's condition to normal by the blood transfusion, he underwent a laparotomy and the Meckel's diverticulum was excised. This is shown in Fig. 62.2.

### What is the embryological origin of a Meckel's diverticulum?

It represents a persistent remnant of the vitello-intestinal duct in the fetus.

\*Johann Friedrich Meckel (1781–1833), Professor of anatomy, Halle, Germany. His father and grandfather both preceded him as professors of anatomy.

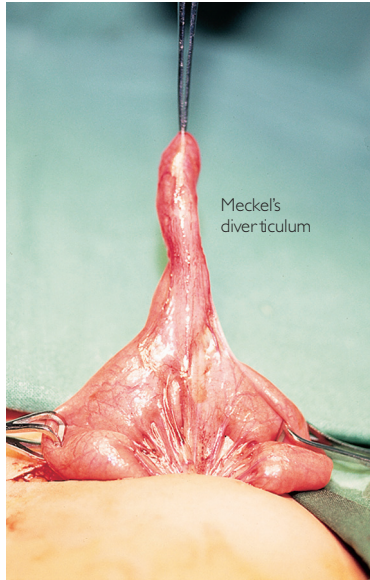


Figure 62.2 Meckel's diverticulum.

**Where is it found and how often is it said to occur?**

The diverticulum lies on the antimesenteric border of the ileum, about 0.6 m from the ileocaecal junction and occurs in about 2% of the population (2 inches long, 2 feet from the ileocaecal valve)..

**The great majority of these diverticula are symptomless and are only discovered incidentally at laparotomy for some other condition or at autopsy. However, those that do cause trouble may do so in a number of ways, what are these?**

- Acute inflammation: Closely mimicking acute appendicitis. If the appendix is found to be normal at operation, the surgeon next looks for a possible Meckel's diverticulum.

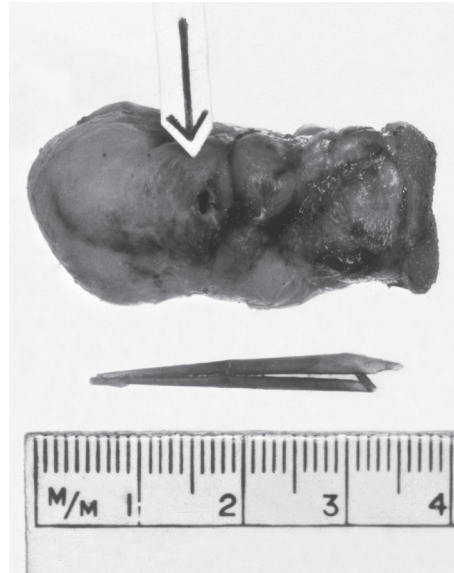

Figure 62.3 A Meckel's diverticulum perforated by a rolled up piece of tomato skin.

- Perforation by a foreign body: A fish bone, chicken bone, toothbrush bristle and many other sharp objects may do this (Fig. 62.3). Again, the preoperative diagnosis is invariably acute appendicitis.
- Diverticulum may invaginate into the ileum and become the head of an intussusception.
- The vitello-intestinal duct may persist right up to the umbilicus, resulting in a small bowel fistula, or the distal end of the duct may present as a 'raspberry tumour' at the umbilicus in the newborn baby.
- A band may pass from the tip of the Meckel to the umbilicus; this band may snare a loop of intestine to produce an acute intestinal obstruction or may act as the apex of a volvulus of the adjacent ileum.
- Peptic ulceration, as in the case of this child, presenting either with haemorrhage or perforation.