

Case 50 Heartburn

A 50-year-old housewife consulted her family practitioner with the request for something to relieve her severe heartburn. When the doctor took a detailed history, this revealed that the patient had been experiencing a burning pain for several years, which she localized to about the middle of the body of the sternum. There was no radiation of the pain. She had been self-medicating, with some success until recently, using a whole variety of proprietary indigestion and antacid tablets and medicines. The pain would come on shortly after her meals, especially her evening dinner, the main meal of the day. She also had her sleep disturbed by the pain and had noticed that this was less likely to happen if she slept propped up with pillows. She also found that the pain might come on if she stooped down, for instance to pick something up from the floor. Occasionally at night or on stooping she had noticed regurgitation of bitter-tasting fluid into her mouth, and this she had found to be particularly unpleasant, but she had never actually vomited.

On direct questioning, she had never noticed the food sticking in the chest on swallowing, i.e. there was no evidence of actual dysphagia. Apart from these symptoms she was well, her appetite good and her bowels acted normally. She had had three children and had gained a lot of weight after the third pregnancy and was now quite obese. Functional enquiry was otherwise normal.

Apart from her obesity and moderate hypertension (blood pressure 160/110), clinical examination was normal.

What is the likely clinical diagnosis based on these findings?

The symptoms are quite typical of a sliding hiatus hernia with gastro-oesophageal reflux. Acid regurgitation into the lower oesophagus produces the pain, which typically occurs after meals (with consequent acid secretion by the stomach) and on lying down, when the cardia of

the stomach herniates through the dilated oesophageal hiatus in the diaphragm.

What is the first-line special investigation to carry out in order to confirm or refute this clinical diagnosis?

Upper gastrointestinal endoscopy is now the investigation of choice when it is available locally. On this occasion the family practitioner referred the patient for a barium swallow and meal examination (Fig. 50.1).

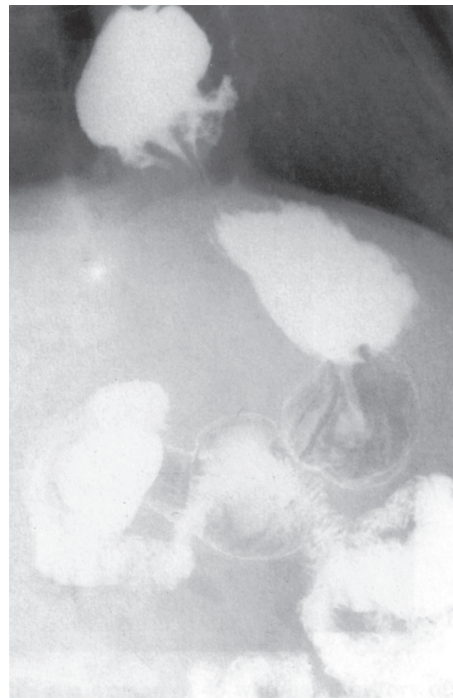


Figure 50.1 Barium swallow and meal examination of the patient.

The deformity shown was constant on a series of films. What does it demonstrate?

There is a large sliding hiatus hernia. The fundus and upper body of the stomach are seen to lie above the crescentic border of the left hemidiaphragm.

What position has the patient been placed in this film?

In order to demonstrate the hernia, the patient has been tipped head-downwards, and is lying on her left side. Note that, in this position, the fundus of the stomach is filled with barium, whereas in the usual erect position of a barium meal examination the fluid level of the gastric air bubble is seen.

In what sort of person is this condition particularly common?

This is the classical case – a middle-aged, obese female.

What symptoms may be associated with a hiatus hernia?

The condition may be entirely symptomless and is discovered when a barium meal or endoscopy is performed for some other cause or when it is found at laparotomy or laparoscopy for some other pathology. Associated oesophageal reflux results in symptoms similar to the present case – burning epigastric or retrosternal pain, which is aggravated by lying down or stooping. Sometimes the chest pain may mimic angina. Longstanding acid reflux may result in stricture formation and bleeding. Barrett's oesophagus* (mucosal gastric metaplasia) may occur in longstanding cases, with the risk of development of adenocarcinoma. A very large hernia may produce mechanical effects – particularly cough and breathlessness.

*Norman Barrett (1903–1979), thoracic surgeon, St Thomas's Hospital, London.