

Case 36

A spinal abnormality in a newborn child

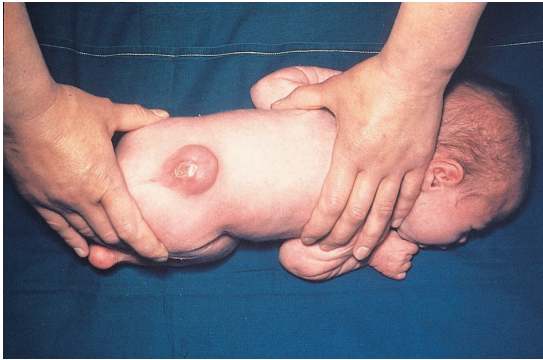


Figure 36.1

Figure 36.1 demonstrates an obvious spinal abnormality in a newborn child. The parents were deeply upset, but at least they were expecting to see this condition.

What is this lesion called?

Spina bifida with meningocele – protrusion of the meninges through the vertebral defect without nervous tissue involvement.

How are the various types of this lesion classified?

The following range of anomalies may be found, in ascending order of severity (Fig. 36.2):

- *Spina bifida occulta*: Failure of vertebral arch fusion only. This is symptomless and is picked up incidentally on spinal X-ray or CT. It may occur anywhere along the spinal column, but the great majority of defects involve L5 (6% of the population) or upper sacrum (11%). It may sometimes be associated with a tuft of hair, a lipoma or an overlying dimple in the skin.
- *Meningocele* (as in this case): Protrusion of the meninges without nervous tissue involvement.

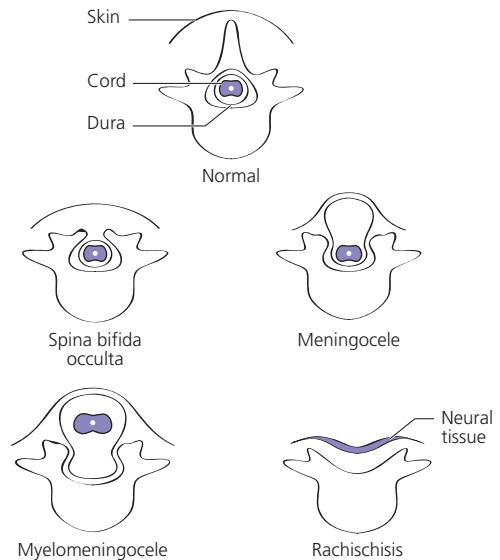


Figure 36.2 The different varieties of spina bifida.

- *Myelomeningocele*: Neural tissue (the spinal cord or roots) protrudes into and may adhere to the meningeal sac.
- *Myelocele* (or rachischisis): Failure of fusion of the neural tube, which results in an open spinal plate that occupies the defect as a red granular area weeping cerebrospinal fluid from its centre. This condition is incompatible with survival.

How did the parents know about this condition before the baby was born?

It is usually detected on the 18–20 week antenatal ultrasound, with confirmatory elevation of the α -fetoprotein (AFP) level and acetylcholinesterase in the amniotic

Part 2: Cases

fluid, enables the defect to be diagnosed with a high degree of confidence. Maternal serum AFP is also raised and may be detected at 16-18 weeks gestation. In severe degrees of this spina bifida, parents may elect for termination of the pregnancy.

What other congenital condition may typically coexist with this lesion?

Hydrocephalus occurs in 75% of cases of myelomeningocele (the Arnold–Chiari malformation, see Case 32, p. 68). Hydrocephalus is very rare in an uncomplicated meningocele, such as in this child.

How should this lesion be treated?

The sac is excised and the skin defect repaired.