

Case 16 A pigmented spot on the face

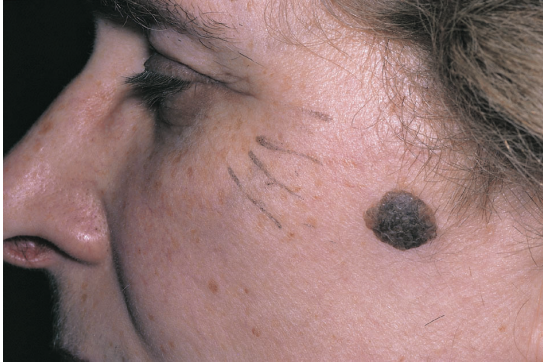

Figure 16.1

This 34-year-old housewife has had this pigmented lesion on her face 'ever since she was a girl' (Fig. 16.1). She does not think it has changed in size but she would now like it removed for cosmetic reasons and because she is worried about what she has read in the papers about malignant melanomas.

How frequent are benign melanomas in the white population?

Nearly everyone with pale skin will have one or more benign melanomas, or 'moles'; often hundreds are present.

What is their cutaneous distribution?

The intradermal melanoma may be found anywhere on the skin apart from the palms of the hands, soles of the

feet, the scrotum or the labia. Junctional melanomas may occur on any part of the skin surface.

This lesion was excised and the histology report came back as an intradermal melanoma. What does that term mean?

An intradermal melanoma is situated entirely in the dermis, where melanocytes form non-encapsulated masses (Fig. 16.2b).

What is meant by a junctional melanoma?

In contrast, the junctional melanoma shows melanocytes clumping together in the basal layer of the epidermis, at the junction between the epidermis and dermis (Fig. 16.2c). It is the junctional melanoma that may, in a small percentage of cases, undergo malignant change (Fig. 16.2c).

When should a pigmented lesion of the skin be removed?

Excision of a pigmented lesion of the skin should be carried out under the following circumstances:

- If the patient is worried about it – and this applies disproportionately among doctors, nurses and medical students – or if it is cosmetically unpleasant.
- If it is situated on the hand, sole, nail bed or genitalia – where it is likely to be a junctional melanoma.
- If the lesion shows any of the features that suggest malignant change might have taken place. This will be considered with Case 17 (p. 35).

Part 2: Cases

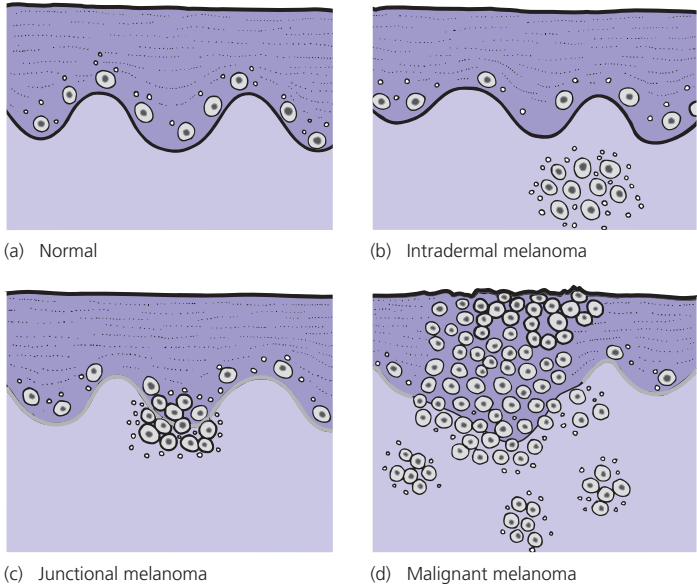


Figure 16.2 (a) Normal skin contains melanocytes (shown as cells) and melanin pigment (shown as dots). The pigment increases in sunburn and freckles. (b) A benign intradermal naevus; the melanocytes are clumped together in the dermis to form a localized benign tumour. (c) A junctional naevus with melanocytes clumping together in the basal layer of the epidermis. These are usually benign but may occasionally give rise to an invasive malignant melanoma (d).