

## Case 9 Burn treatment

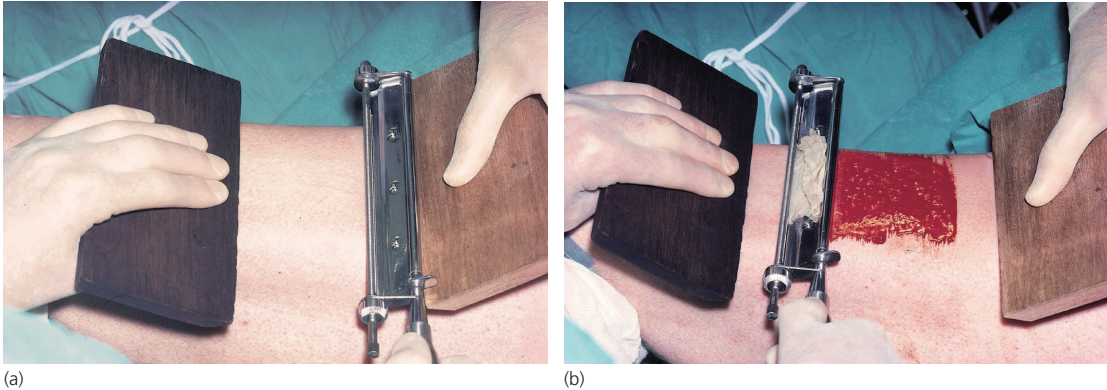


Figure 9.1

Figure 9.1 shows the stages of the operation performed on the thigh of the patient discussed in Case 8 (p. 18) on the next day.

### What operation is being performed?

Skin is being taken in order to perform a skin graft.

### What layer of skin is being removed by the surgeon?

This is a split-skin graft, being taken through the germinal layer of the epithelium (see Fig. 8.3), and leaving islands of the layer on the donor site. The surgeon can tell that he is in the right plane because the sheet of skin he is taking is translucent, while on the donor site there is punctuate bleeding of the areas of dermis between the islands of residual epithelium.

### What will happen to the raw area left behind on the patient's thigh?

This is dressed with paraffin gauze covered with a sterile gauze dressing. The remaining islands of germinal epithelium at the donor site will proliferate, so that the raw area will become re-epithelialized in about 10 days. In very extensive full thickness burns, the donor sites can be re-utilized over and over again.

### What are the areas of priority for grafting in patients with extensive full thickness burns?

The eyelids have top priority, followed by the face, hands and flexor aspects of the joints. These are the areas where scarring contractures would produce considerable deformity and disability.