

Case 2 Inside out

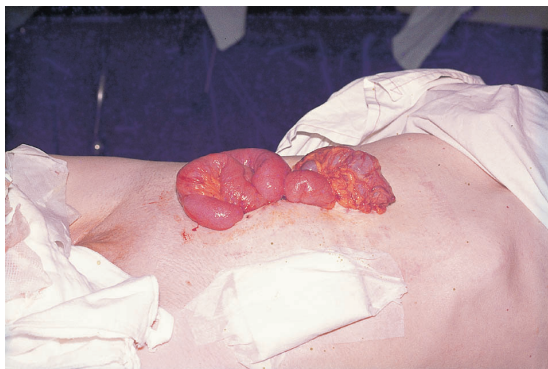


Figure 2.1

A civil engineer aged 58 years had a right hemicolectomy performed through a right paramedian incision for a carcinoma of the caecum. Postoperatively he developed quite a severe pulmonary collapse at both lung bases, which responded to vigorous chest physiotherapy. He also had a prolonged period of paralytic ileus and required nasogastric suction and intravenous fluids until flatus was passed on the seventh postoperative morning. During this time he was troubled with considerable abdominal distension. On the tenth postoperative day he had a spell of coughing and called the nurses because of the unpleasant sight shown in Fig. 2.1. The patient was, not surprisingly, very frightened, but was in no more than moderate discomfort.

What is this condition called?

The common term applied to this is burst abdomen. The rather more mellifluous expression is abdominal wall dehiscence.

What may be a warning sign of this before the abdominal wound completely ruptures?

The 'pink fluid sign'. This is produced by serous peritoneal exudate, tinged with blood and hence pink in colour,

which oozes through the breaking down abdominal wound, sometimes for several days before complete dehiscence occurs.

The only other cause of such a discharge, which should be quite obvious, is the discharge of a large subcutaneous haematoma. The final disruption of all layers of the wound occurs either as a result of the patient coughing or straining, or when the skin sutures – the last things holding the edges of the wound together – are removed, usually around the tenth postoperative day.

If this sign is detected, the patient should be returned to the theatre and the wound explored under a general anaesthetic before complete rupture takes place.

How would you classify the factors that may be responsible for this emergency?

As in Case 1, the classification is into preoperative, operative and postoperative factors.

- *Preoperative factors:* These include factors that impair normal wound healing. These are numerous and include, most importantly, vitamin C deficiency, protein deficiency, jaundice, uraemia and anaemia, several of which may occur in the same patient, for example, one with advanced malignant disease. Preoperative factors that are likely to place undue strain on the surgical wound include chronic cough and abdominal distension.
- *Operative factors:* These are due to faulty technique – the sutures may have been poorly placed too near the wound edge, poorly tied or knotted, or the ends cut off too near the knot. The suture material to repair the abdominal wound should be non-absorbable (e.g. nylon) or only slowly absorbable (e.g. polydioxanone, PDS) material, and should not be too fine, and therefore readily breakable.

Numerous controlled randomized and prospective studies have shown the value of the 'mass closure' technique of suturing the abdominal wound. All the layers of the abdominal wall apart from the skin and subcutaneous fascia are picked up a minimum of 1 cm from the wound

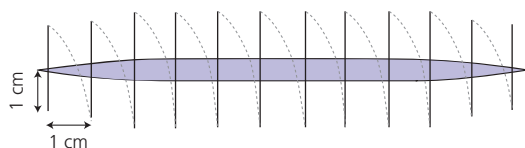


Figure 2.2 Jenkin's rule – the amount of the suture should be at least four times the length of the wound.

edge on either side and the sutures inserted 1 cm or less apart. The skin is closed as a separate layer. The formula is that, for a continuous suture, the length of suture used should be at least four times the length of the wound (T.P.N. Jenkins' rule), with sutures 1 cm apart and with 1 cm bites of the wound edge (Fig. 2.2).

- *Postoperative factors:* These are factors that either place undue strain on the abdominal wound (for example, postoperative cough or abdominal distension) or that weaken the tissues on either side of the incision – wound sepsis is important in this context.

How would you manage this situation?

- In every emergency, provided that your patient is conscious, remember that the first thing to do is to reassure the patient (and his relatives); in this particular instance he will certainly be terrified.
- Next give analgesia such as intravenous morphine, both as a sedation and pre-anaesthetic medication, together with an anti-emetic to prevent opiate-induced retching that might result in more bowel leaving the abdomen.
- The intestines cannot be reduced due to the rigidity of the abdominal wall; do not even attempt to do so. Cover the exposed viscera with a sterile towel or large dressing, soaked in warmed normal saline, and keep this in place with a bandage. Arrange immediate transfer to the operating theatre. A general anaesthetic is required to relax the abdominal wall muscles and to allow reposition of the prolapsed viscera.
- Repair is carried out using interrupted nylon sutures, which are passed through all layers of the abdominal wall, including the skin (Fig. 2.3). The sutures are held open

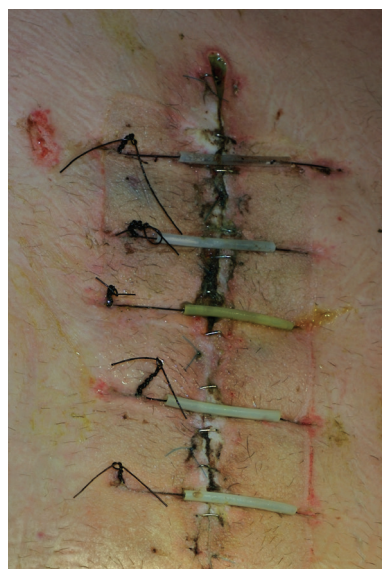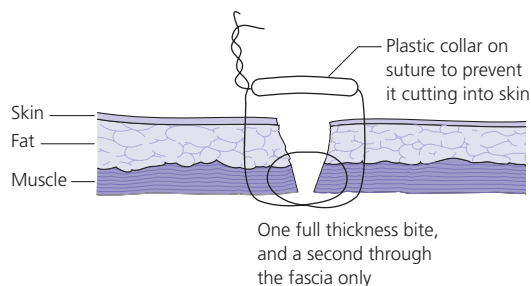


Figure 2.3 (a) Deep tension sutures pass through all layers of the abdominal wall with double bites of the musculo-fascial layer. The plastic collar (b) prevents the suture cutting into the skin while the suture is in place, typically six weeks.

until all are inserted and then tied *seriatim*, great care being taken not to damage the underlying viscera.

If the deep layers of the abdominal wound give way but the skin sutures hold, what will result?

An incisional hernia.